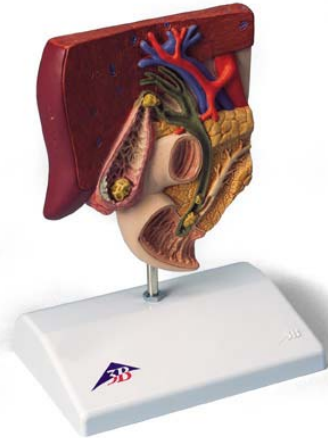


## D4 – Gallstone



1. liver
2. left hepatic duct
3. right hepatic duct
4. common hepatic duct
5. gallbladder
6. neck of gallbladder
7. body of gallbladder
8. fundus of gallbladder
9. mucosal fold
10. spiral fold
11. cystic duct
12. common bile duct
13. major duodenal papilla
14. duodenum
15. sphincter ampullae muscle
16. abdominal aorta
17. portal vein of liver
18. pancreatic duct
19. pancreas
20. gallstone in the fundus area of the gallbladder
21. gallstone in the area of the spiral valve
22. wall area with acute inflammation of the gallbladder wall
23. wall area following chronic inflammation of the gallbladder wall (scarred, contracted and thickened)
24. gallstone in the area of the common bile duct
25. a stone obstructing the papillary opening to the small intestine. consequently, drainage of the common bile duct and the pancreatic duct is obstructed.

# D4 – Gallstone

