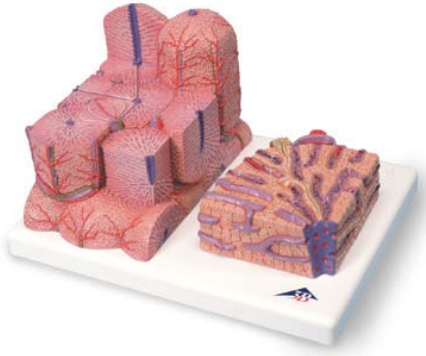


## D6 – Microanatomy of Liver



1. central vein
2. portal liver lobule
3. portal canal
4. liver acinus
5. zone 1
6. zone 2
7. zone 3
8. classic liver lobule
9. interlobular bile duct
10. interlobular artery
11. interlobular vein
12. cell of Kupffer
13. hepatocyte
14. terminal bile duct (Herring's canal)
15. liver sinusoids
16. bile canaliculi

# D6 – Microanatomy of Liver

