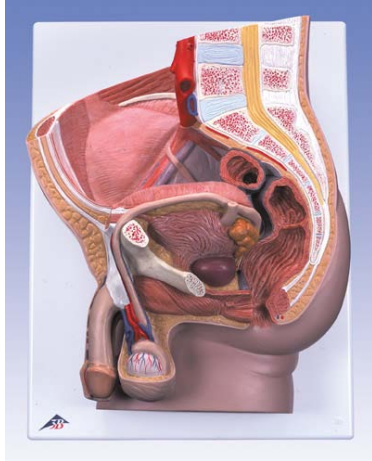
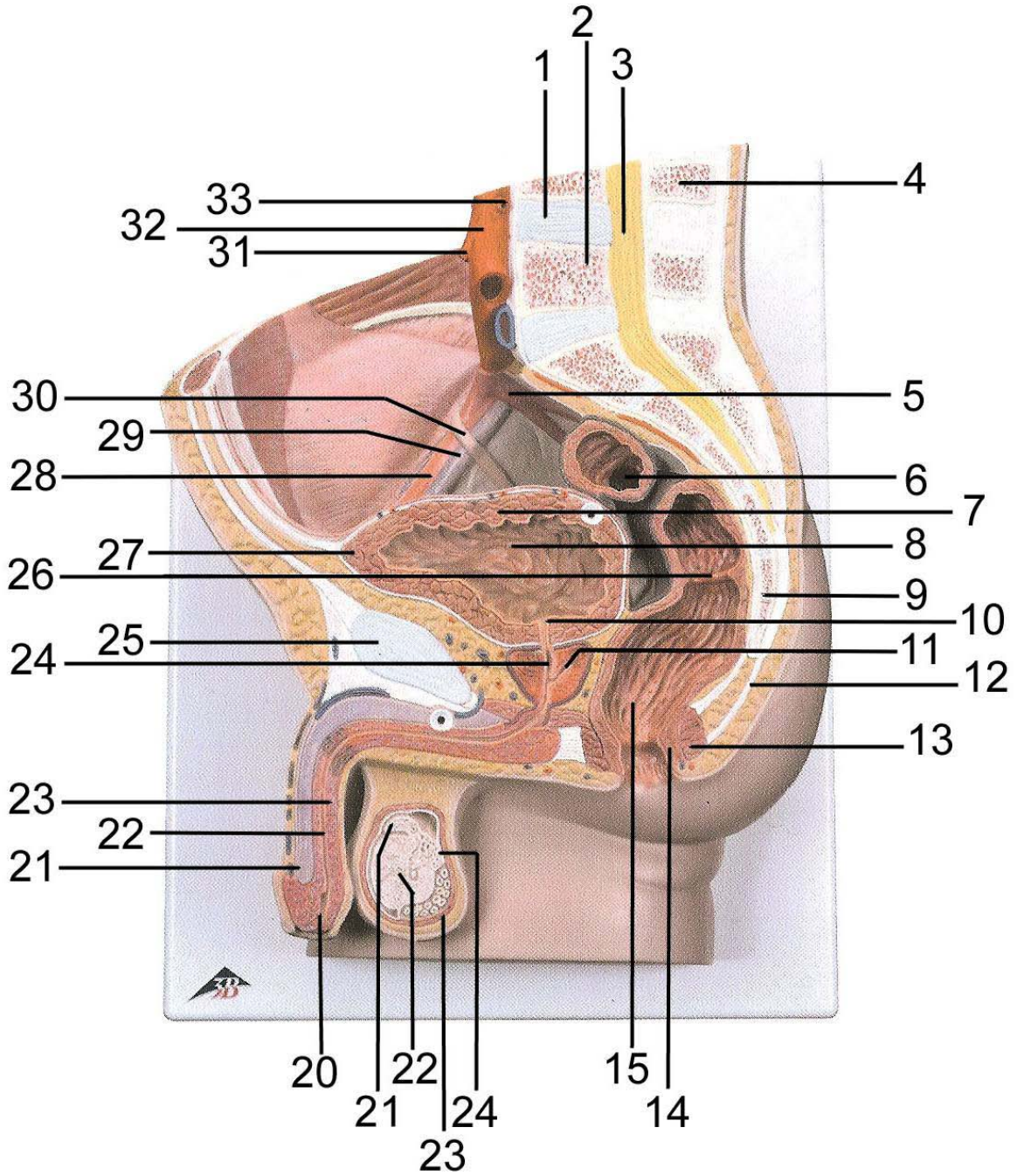


REP1 – Male Pelvis

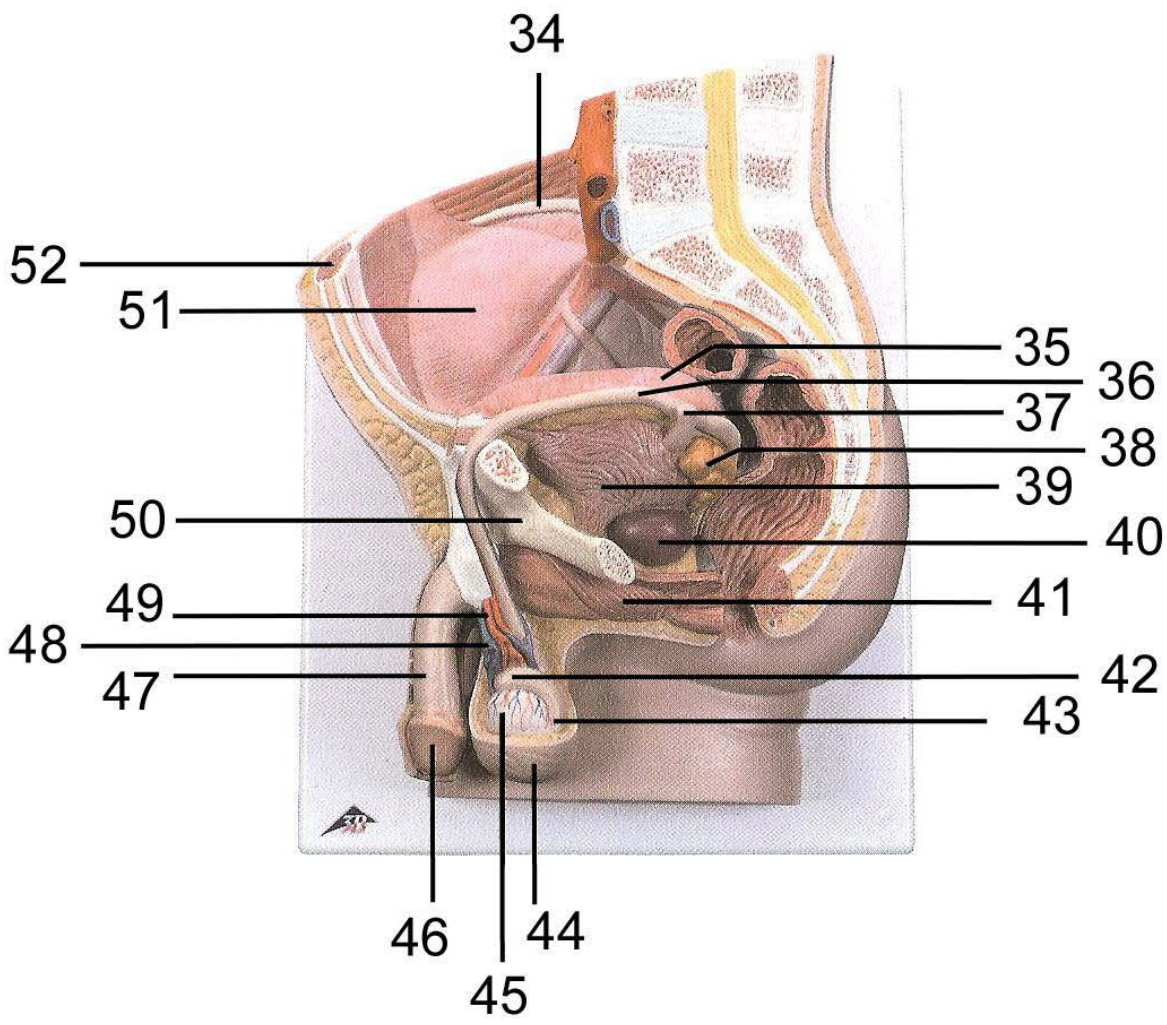


1. Intervertebral disc
2. Lumbar vertebra
3. Spinal marrow
4. Spinous process
5. Internal iliac artery
6. Sigmoid colon (pelvic colon)
7. Muscular coat of bladder
8. Fundus of bladder (Vortex of bladder)
9. Coccygeal bone
10. Internal urethral orifice
11. Prostatic utricle
12. Anococcygeal ligament
13. Sphincter ani externus muscle
14. Sphincter ani internus muscle
15. Rectal ampulla
16. Cauda of epididymis
17. Cremaster muscle
18. Testis
19. Head of epididymis
20. External opening of masculine urethra
21. Cavernous body of penis
22. Spongy part of masculine urethra
23. Spongy body of penis
24. Masculine urethra, prostatic part
25. Pubic symphysis
26. Transverse rectal fold
27. Apex of urinary bladder
28. External iliac artery
29. External iliac vein
30. Right Ureter
31. Inferior mesenteric artery
32. Abdominal aorta
33. Renal artery
34. Crest of ilium
35. Bladder
36. Deferent duct (spermatic duct)
37. Left Ureter
38. Seminal vesicle
39. Muscular coat of bladder
40. Prostate
41. Bulbospongiosus muscle
42. Head of epididymis
43. Cauda of epididymis
44. Scrotum
45. Testis
46. Glans of penis
47. Penis
48. Spermatic plexus
49. Testicular artery
50. Pubic bone
51. Visceral peritoneum
52. Rectus abdominis muscle
53. Bladder
54. Deferent duct (spermatic duct)
55. Right Ureter
56. Right testicular artery
57. Right testicular vein
58. Rectus abdominis muscle
59. Aponeurosis of Obliquus externus abdominis muscle
60. Obliquus internus abdominis muscle
61. Transversus abdominis muscle
62. Renal pelvis
63. Renal cortex
64. Quadratus lumborum muscle
65. Latissimus dorsi muscle Erector spinae muscle
66. Psoas major muscle

REP1 – Male Pelvis



REP1 – Male Pelvis



REP1 – Male Pelvis

