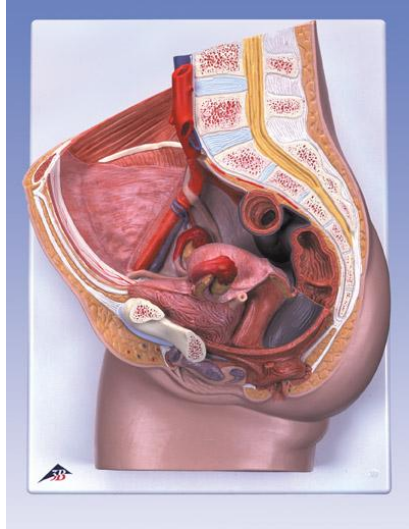
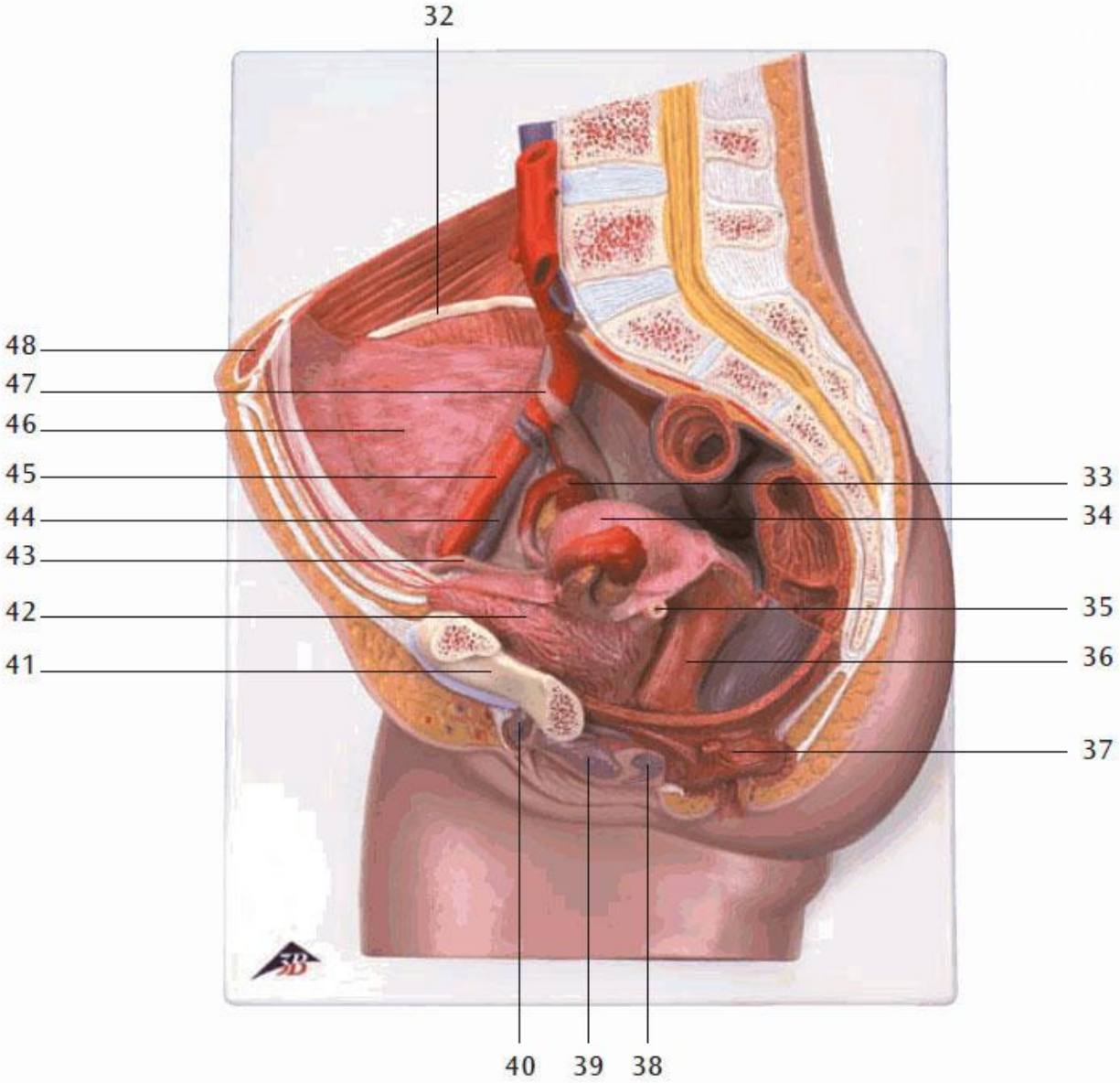


REP2 – Female Pelvis



1. Intervertebral disc
2. Lumbar vertebra
3. Spinal marrow
4. Spinous process
5. Internal iliac artery
6. Sigmoid colon (pelvic colon)
7. Uterine cavity
8. Supravaginal part of cervix uteri
9. Transverse rectal fold
10. Coccygeal bone
11. Opening of uterus
12. Rectal ampulla
13. Anococcygeal ligament
14. Sphincter ani externus muscle
15. Sphincter ani internus muscle
16. Vagina
17. Lesser pudendal lip
18. Greater pudendal lip
19. Cavernous body of clitoris
20. Feminine urethra
21. Pubic symphysis
22. Bladder
23. Fundus of uterus
24. External iliac vein
25. External iliac artery
26. Ovarian vein
27. Ovarian artery
28. Inferior mesenteric artery
29. Renal artery
30. Abdominal aorta
31. Inferior vena cava
32. Crest of ilium
33. Ovary
34. Intestinal surface of uterus
35. Left Ureter
36. Vagina
37. Sphincter ani externus muscle
38. Greater vestibular gland (BARTHOLINI)
39. Vestibula of vagina
40. Clitoris
41. Pubic bone
42. Bladder
43. Round ligament of uterus
44. External iliac vein
45. External iliac artery
46. Visceral peritoneum
47. Right Ureter
48. Rectus abdominis muscle
49. Ovarian canal (uterine tube)
50. Uterus
51. Ampulla of uterine tube
52. Ovarian ligament
53. Round ligament of uterus
54. Rectus abdominis muscle
55. Ureter
56. Obliquus externus abdominis muscle
57. Obliquus internus abdominis muscle
58. Transversus abdominis muscle
59. Renal cortex
60. Renal cortex
61. Latissimus dorsi muscle
62. Quadratus lumborum muscle
63. Psoas major muscle
64. Erector spinae muscle
65. Psoas minor muscle
66. Ovarian ligament
67. Ovary

REP2 – Female Pelvis



REP2 – Female Pelvis

