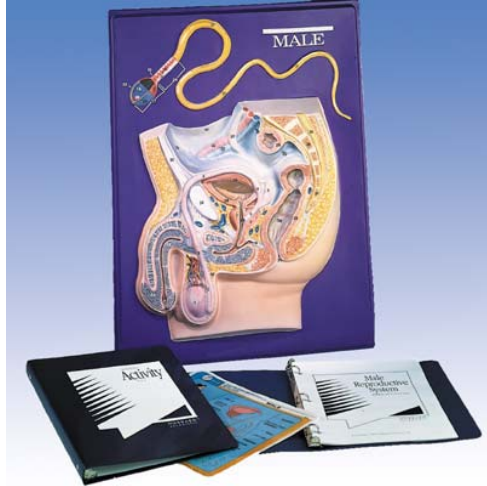


Rep 5 – Male Reproductive



Organs and structures primarily associated with reproduction

1. testis
2. epididymis
3. ductus deferens
4. ampulla of ductus deferens
5. seminal vesicle
6. ejaculatory duct
7. prostate gland
8. bulbourethral gland
9. urethra
10. penis
11. corpus cavernosum of penis
12. corpus spongiosum of urethra
13. glans of penis
14. fossa navicularis of urethra
15. prepuce
16. scrotum

The spermatozoon

17. head of sperm
18. nucleus
19. vacuole
20. anterior head cap
21. posterior head cap
22. surface membrane
23. neck
24. body or middle piece
25. axial filament
26. mitochondria
27. tail

Other pelvic organs and structures

28. urinary bladder
29. sigmoid colon
30. rectum
31. anus
32. external iliac artery and vein
33. hypogastric artery
34. pubic symphysis
35. linea alba
36. sacrum
37. coccyx bone
38. cauda equine
39. peritoneal cavity