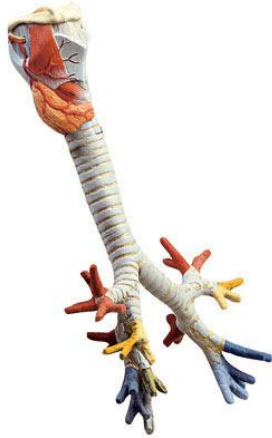


# RES5 – Larynx, Trachea and Bronchial Tree



## Larynx

1. hyoid (tongue bone)
  - a. body
  - b. greater cornu
  - c. lesser cornu
2. thyroid cartilage
  - d. superior cornu of the thyroid cartilage
  - e. inferior cornu of the thyroid cartilage
3. cricoid cartilage
4. arytenoid cartilage
5. corniculate cartilage (also called cartilage of Santorini)
6. cuneiform cartilage (also called wrisberg's cartilage)
7. tracheal cartilages (also called windpipe cartilages)
8. middle ligament of the tongue
9. lateral ligament of the tongue bone and the thyroid cartilage
10. joint-capsule between thyroid cartilage horn and cricoid cartilage
11. crico-thyroid ligament
12. ligament of the cricoid cartilage and the windpipe
13. elastic fibrous substance between the tracheal cartilages
14. posterior membranous wall of the windpipe
15. thyrohyoid muscle
16. crico-thyroid muscle
17. posterior crico-arytenoid muscle
18. transverse arytenoid muscle
19. oblique arytenoids muscle
20. superior thyroid artery
21. superior laryngeal artery
22. superior laryngeal nerve
23. epiglottis
24. ligament of the tongue bone and the epiglottis
25. thyro-epiglottic ligament
26. sinus of the larynx

# RES5 – Larynx, Trachea and Bronchial Tree

27. vestibular fold (also called false vocal cord)
28. false vocal cord with true vocal cord
29. vocal muscle
30. mucous membrane of windpipe
31. ary-epiglottic folds
32. piriform fossa

## Bronchial Tree

### A. primary bronchus (right)

1. bronchus segmentalis apicalis
2. bronchus segmentalis posterior
3. bronchus segmentalis anterior
4. bronchus segmentalis lateralis
5. bronchus segmentalis medialis
6. bronchus segmentalis apicalis (superior)
7. bronchus segmentalis basalis medialis
8. bronchus segmentalis basalis anterior
9. bronchus segmentalis basalis lateralis
10. bronchus segmentalis basalis posterior

### B. primary bronchus (left)

1. bronchus segmentalis apicoposterior
2. bronchus segmentalis apicoposterior
3. bronchus lingularis superior
4. bronchus lingularis inferior
5. bronchus segmentalis apicalis (superior)
6. bronchus segmentalis anterior
7. bronchus segmentalis lateralis
8. bronchus segmentalis posterior