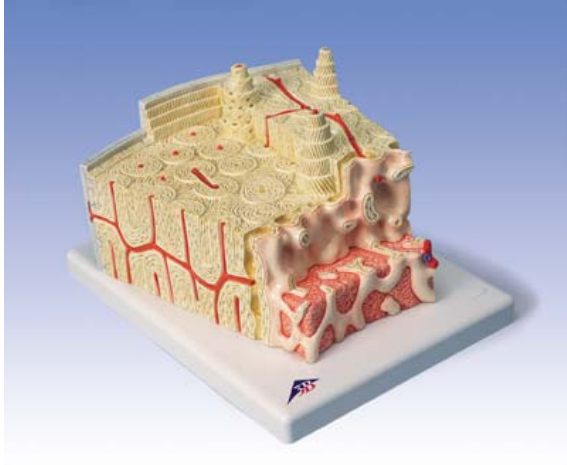
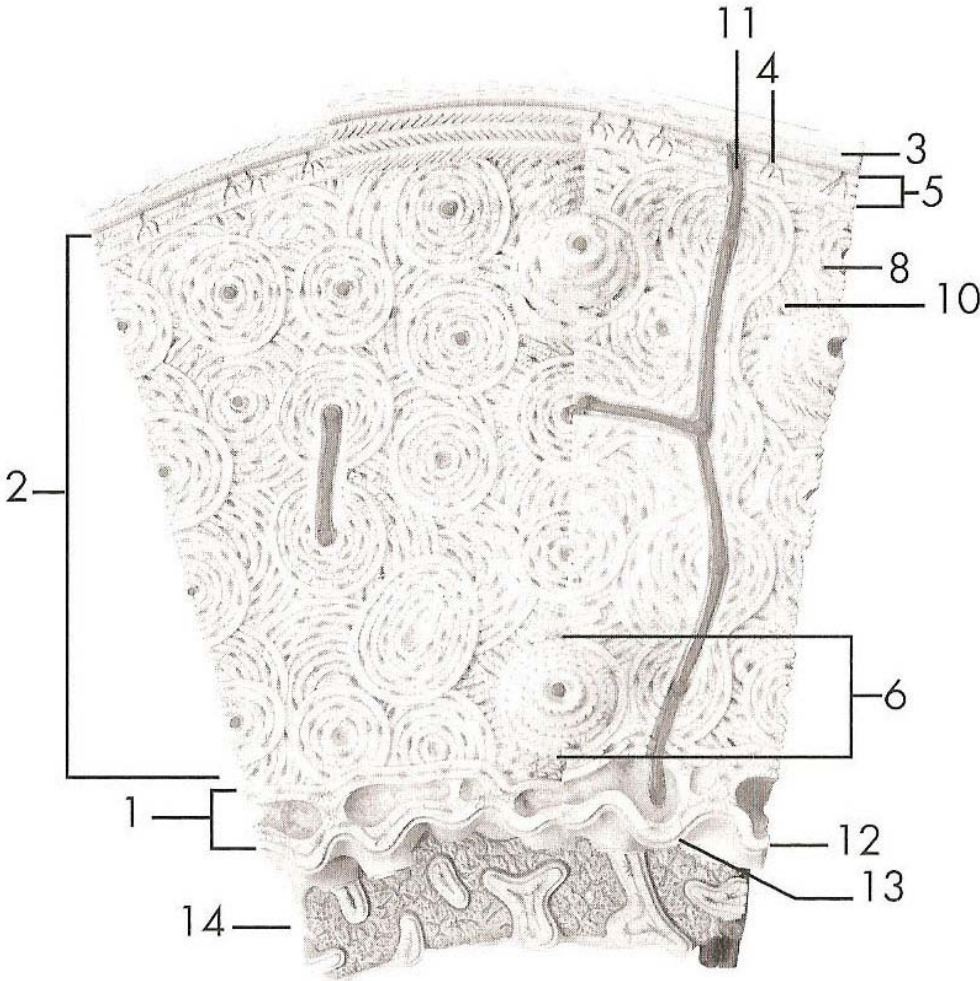


# S12 – Bone Microanatomy

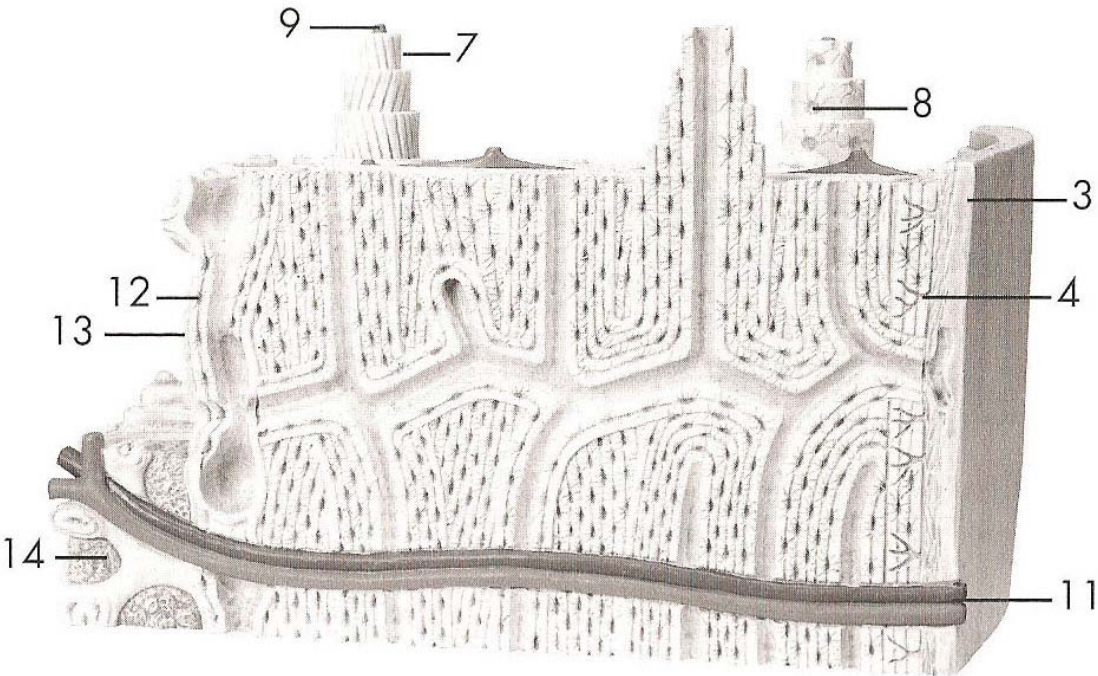
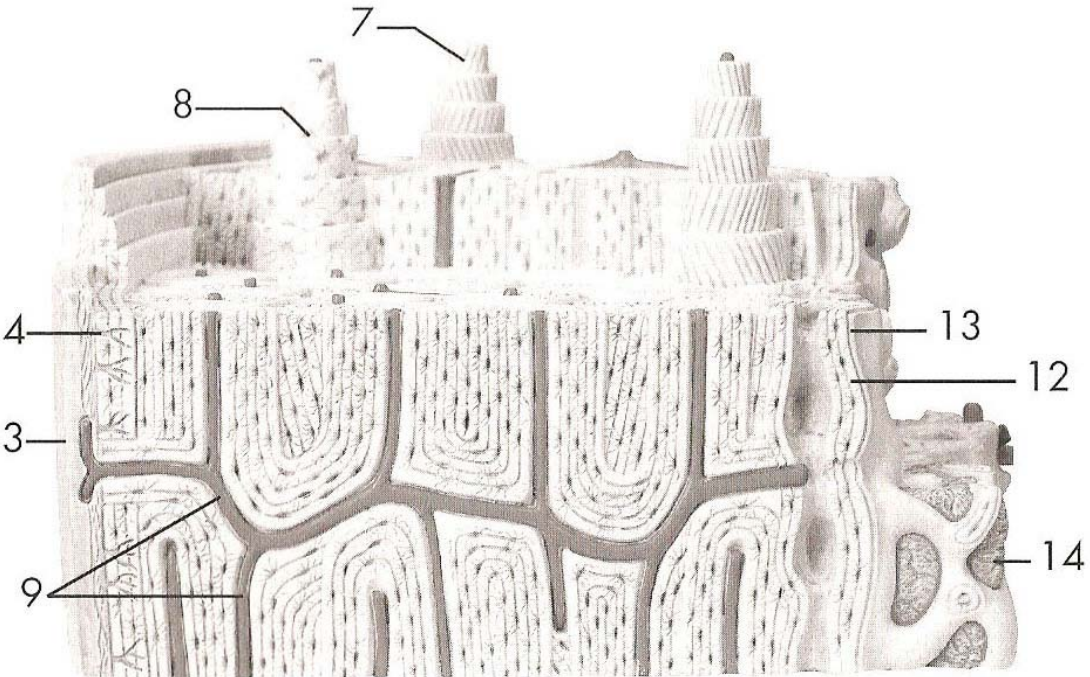


1. spongy bone
2. compact bone
3. periosteum
4. perforating fibers
5. outer circumferential lamella
6. osteons
7. lamellae of the osteons
8. osteocytes
9. Haversian (or central) canals with blood arteries and veins
10. intermediate lamellae
11. Volkmann canals
12. inner circumferential lamella
13. endosteum
14. bone marrow

# S12 – Bone Microanatomy



# S12 – Bone Microanatomy



# S12 – Bone Microanatomy

